



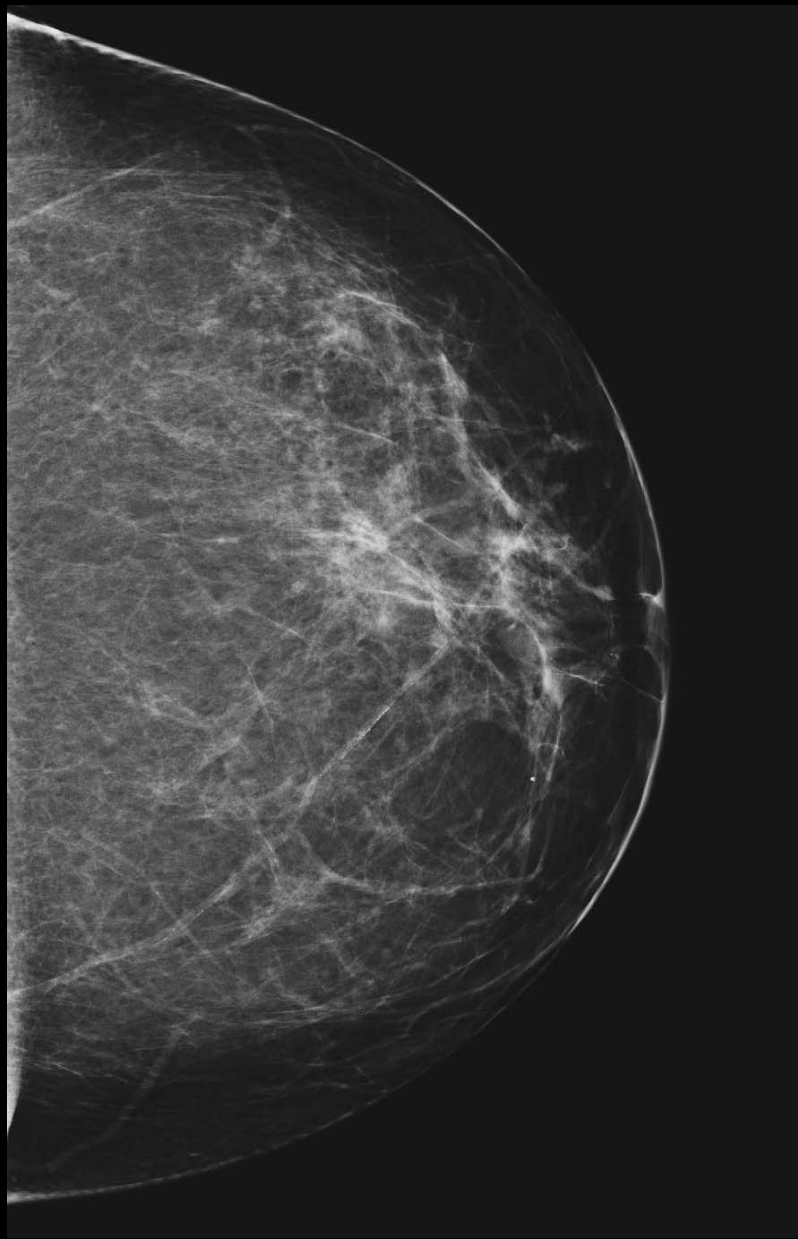Breast Tomosynthesis example images

Caution: Experimental device limited to investigational use. Not approved for sale by the FDA

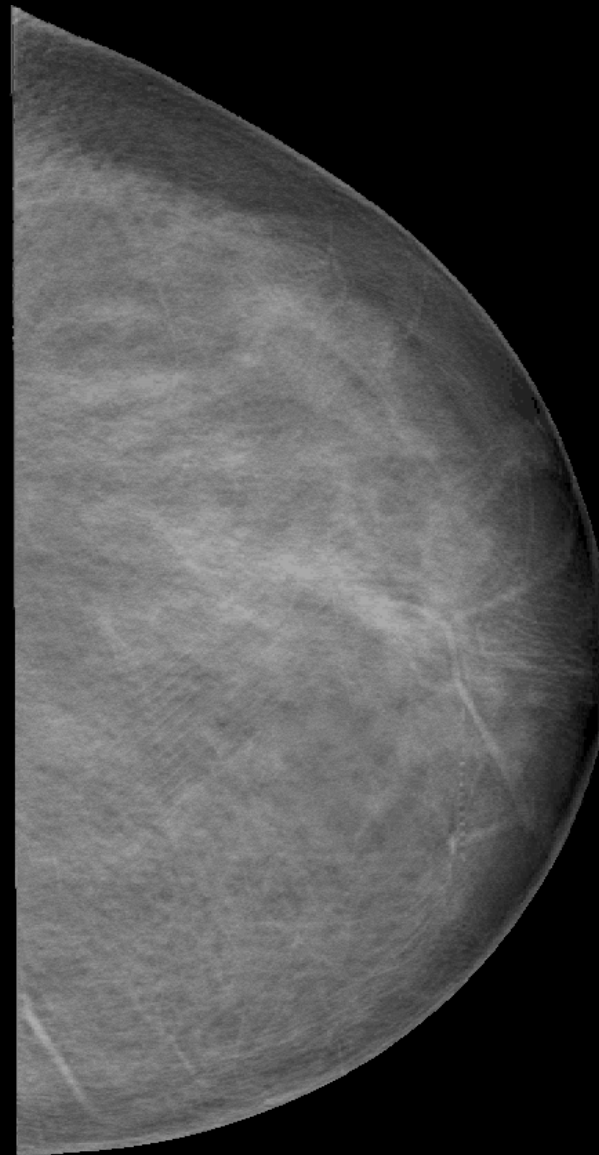Clinical Examples

- Courtesy of:
 - Dartmouth Hitchcock Medical Center, Lebanon NH
USA
 - University of Iowa, Iowa City, IA USA

Selenia Mammogram

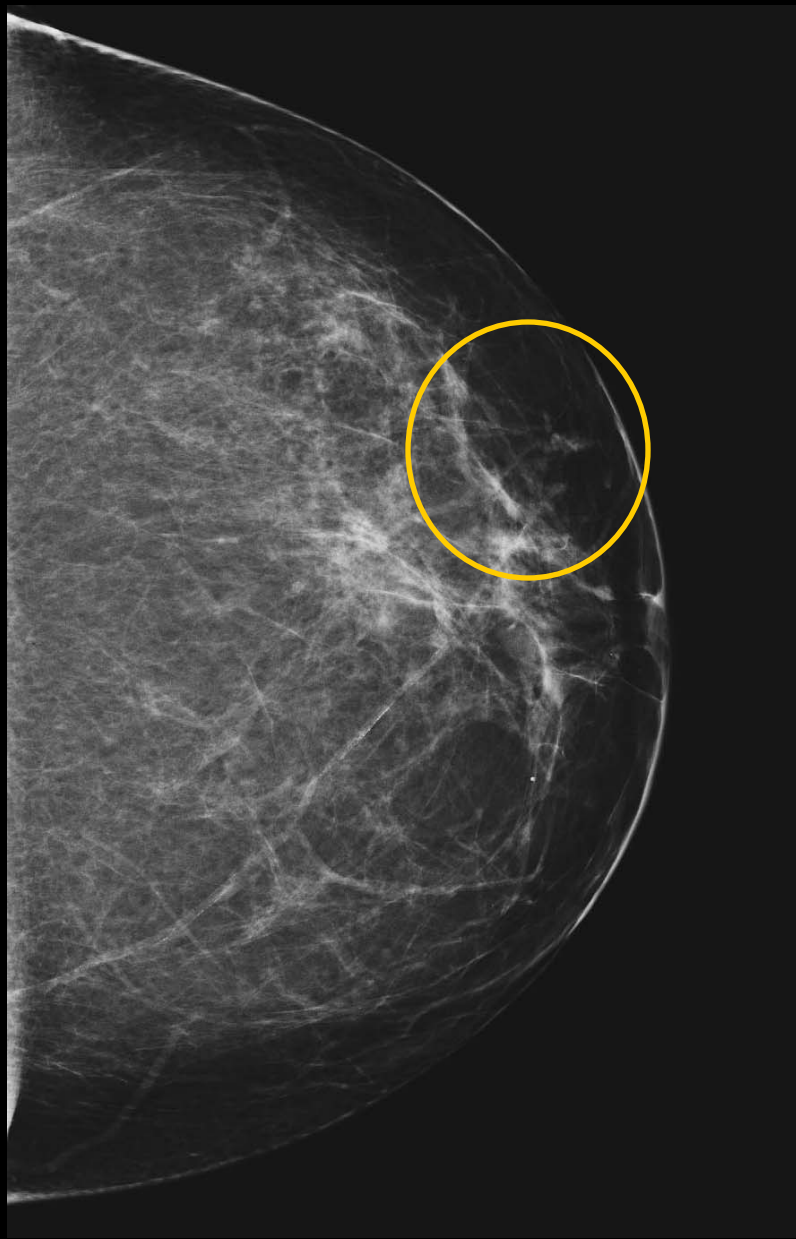

Selenia Tomosynthesis

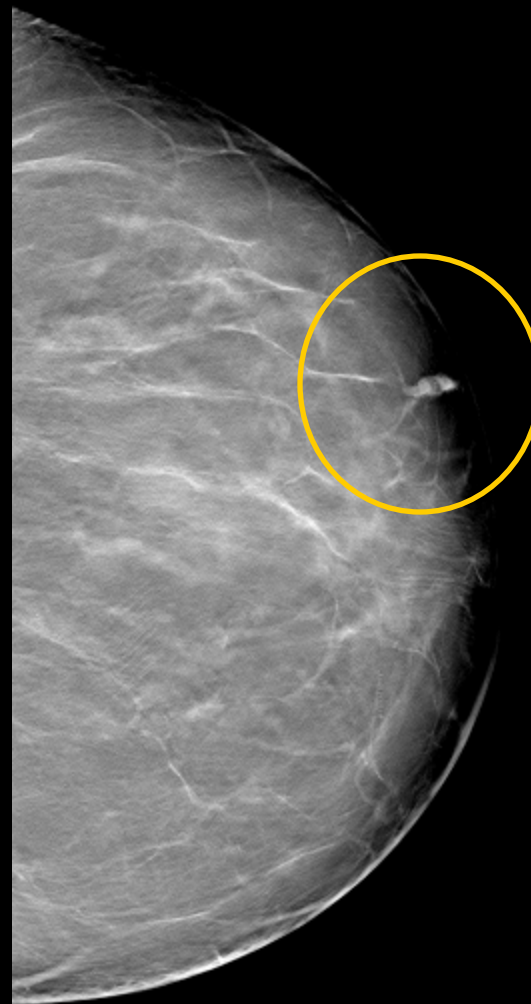


Mammo false negative: mammo missed biopsy proven cancer

Selenia Mammogram

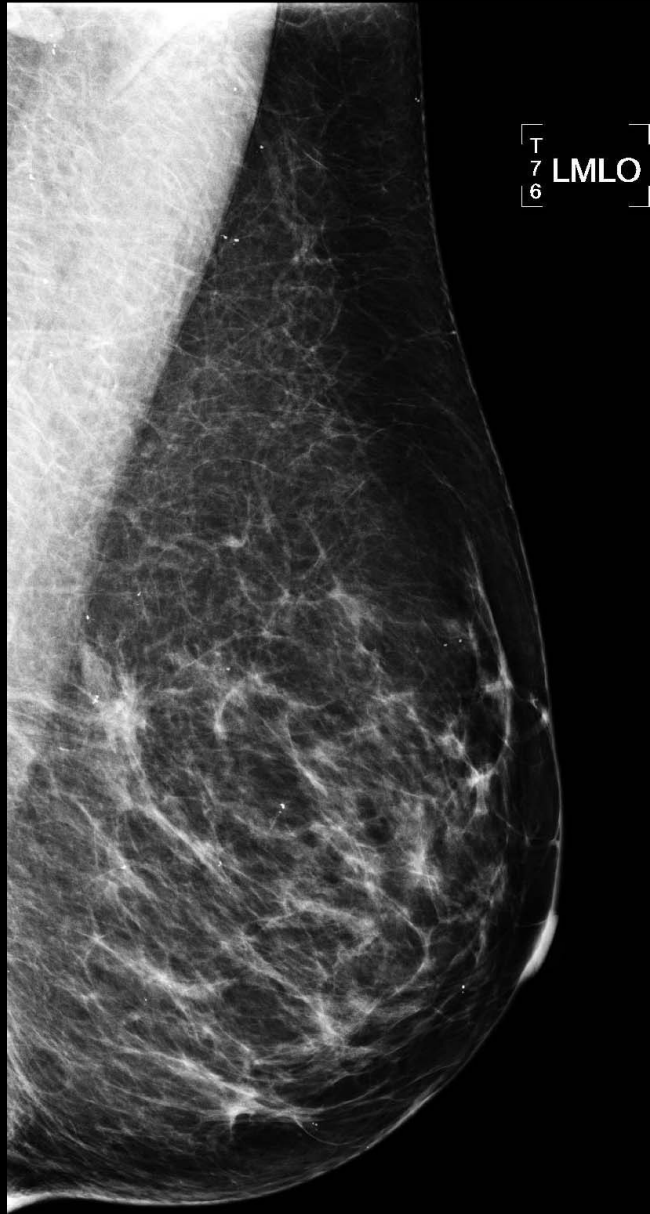


Selenia Tomosynthesis

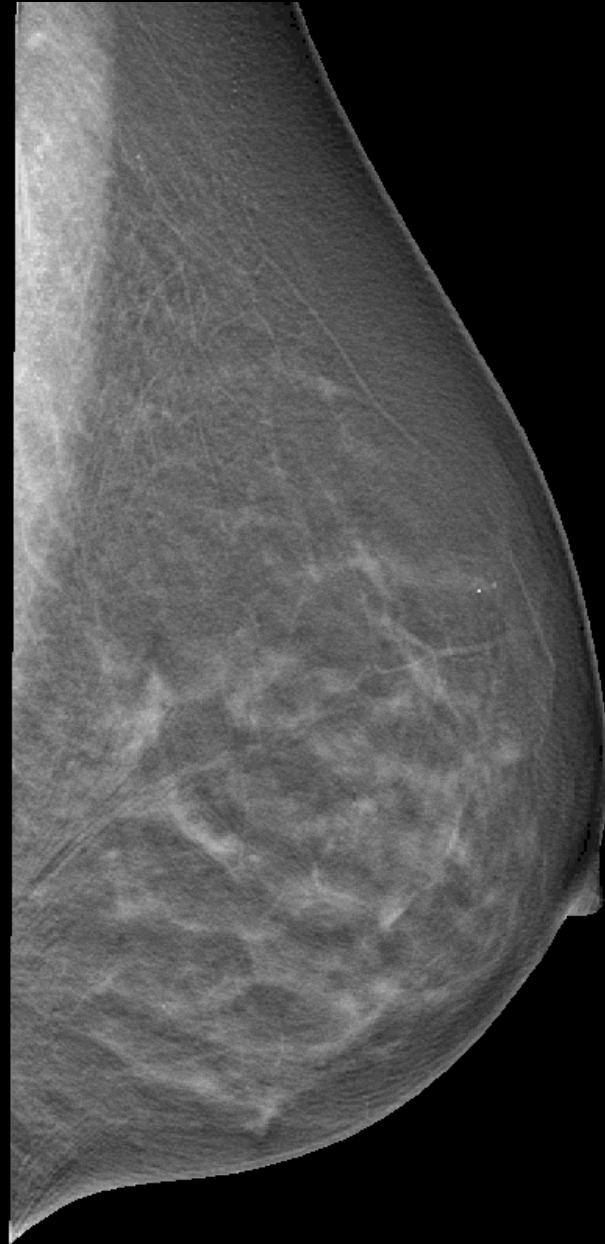


Mammo false negative: mammo missed biopsy proven cancer

Selenia Mammogram

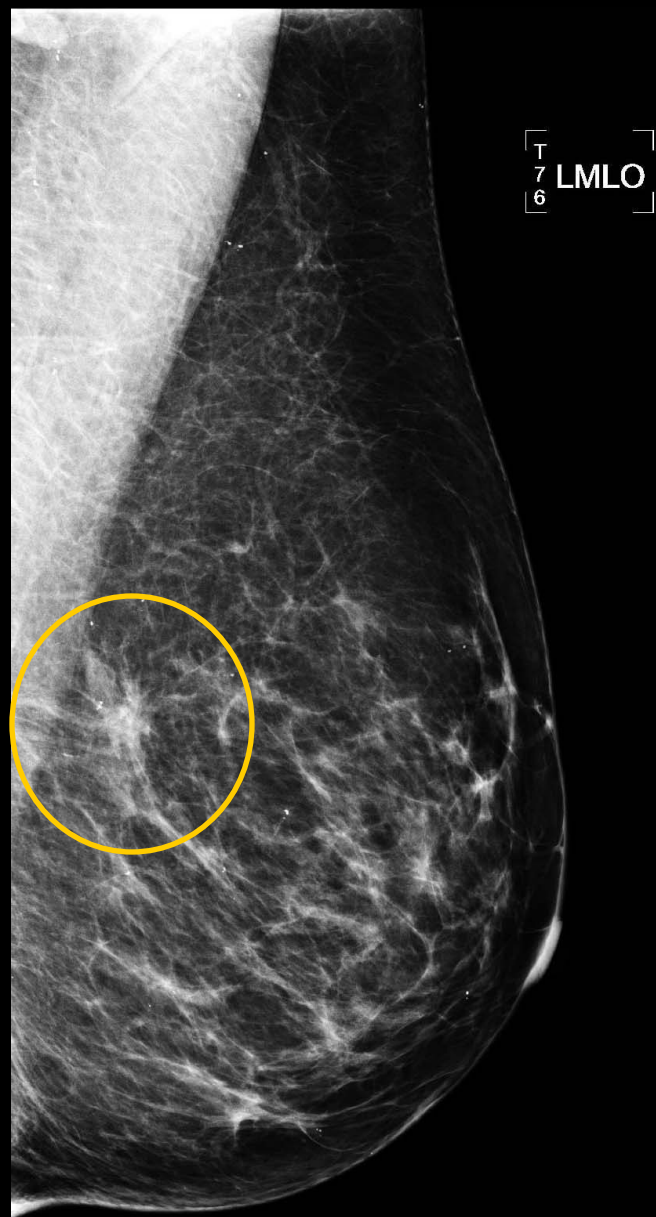

Selenia Tomosynthesis

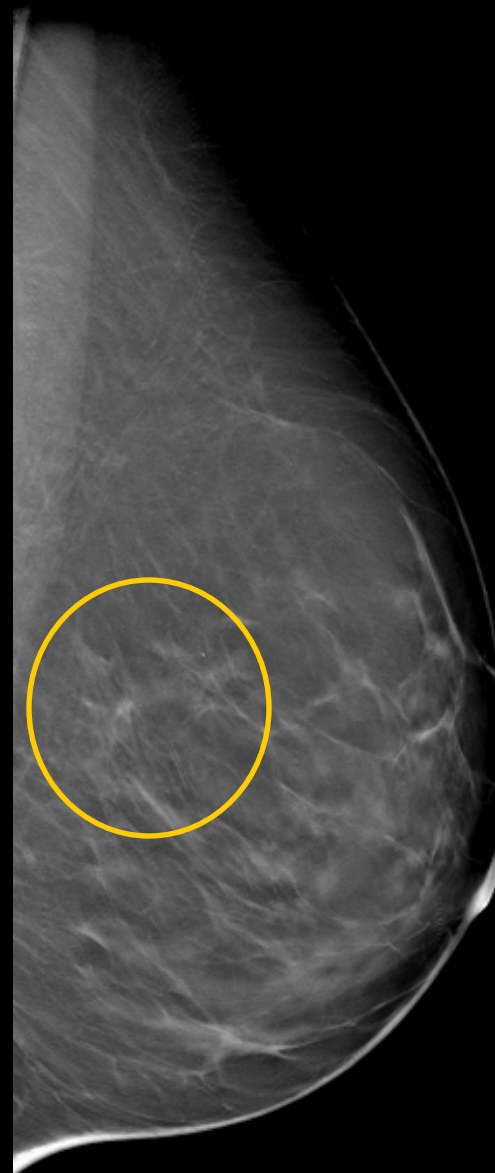

Mammo false positive. Benign. Superimposed parenchyma

Selenia Mammogram



Selenia Tomosynthesis



Mammo false positive. Benign. Superimposed parenchyma